

Peri-Implant Bone Level Around Implants with Platform-Switched Abutments

Stefan Fickl, Dr Med Dent¹/Otto Zuhr, Dr Med Dent²/Jamal M. Stein, Dr Med Dent³/
Markus B. Hürzeler, Prof Dr Med Dent^{2,4}

Purpose: The purpose of this clinical trial was to evaluate whether the crestal bone height around dental implants could be influenced by the use of a platform-switching protocol. **Materials and Methods:** All implants placed in the year 2006 in healed bone without any need for ridge augmentation were included in this study. The following groups were created: (1) wide-diameter implants were placed subcrestally and regular-diameter cover screws were connected; (2) regular-diameter implants were placed at the crest and regular-diameter cover screws were connected. Standardized radiographs were obtained after insertion of the definitive prosthesis and after 1 year. Calibrated measurements were conducted initiating from the mesial and distal bone peaks to the implant-abutment junction. The average value of the mean medial and mean distal values was calculated and analyzed with an unpaired two-tailed t test. P values < .05 were regarded as statistically significant. **Results:** In all, 89 dental implants in 36 patients were evaluated. The implants with a platform-switched configuration (n = 75) exhibited statistically significantly less bone loss at time of insertion of the definitive prosthesis (0.30 ± 0.07 mm versus 0.68 ± 0.17 mm; $P < .05$) and at 1 year (0.39 ± 0.07 mm versus 1.00 ± 0.22 mm, $P < .01$) when compared to the nonplatform-switched implants (n = 14). **Conclusion:** Platform-switched implants seem to limit crestal bone remodeling. INT J ORAL MAXILLOFAC IMPLANTS 2010;25:577–581

Key words: bone preservation, crestal bone level, platform switching

Replacement of missing teeth by means of endosseous implants has been proven to be a predictable and successful treatment modality.^{1–3} However, two-piece implants are frequently associated with postrestorative crestal bone level alterations of about 1 to 2 mm during the first year of loading.^{4,5} As a consequence, an implant is defined as successful only when the peri-implant bone loss does not exceed 2 mm in the first year of function and remains less than 0.2 mm annually thereafter.⁵

The peri-implant soft tissue complex consists of a junctional epithelium and connective tissue, resulting in a 3- to 4-mm-wide zone of biologic soft tissue coverage of the bone supporting the implant.^{6,7} It has been

reported that the corresponding peri-implant crestal bone levels are dependent upon the location of the implant-abutment junction (IAJ) in relation to the bone crest, suggesting that bone loss could be limited if the implant shoulder was located above the alveolar crest.^{8,9} Furthermore, crestal resorption is not evident as long as the implant remains completely submerged but develops once an implant has been exposed to the oral environment.¹⁰ Therefore, the formation of the biologic soft tissue coverage and the location of the IAJ with its inevitable microgap¹¹ have been implicated as key factors in peri-implant bone remodeling.

Ericsson et al found histologic evidence that an inflammatory cell infiltrate is located 1 to 1.5 mm adjacent to the IAJ.¹² Considering the fact that bone is always encircled by approximately 1 mm of healthy connective tissue,¹² it can be assumed that crestal bone remodeling may take place to establish space between the bone and the microbial contaminated tissue of the IAJ to create a biologic seal. Furthermore, Berglundh and Lindhe confirmed that approximately 3 mm of peri-implant mucosa is required to generate a mucosal seal around dental implants.⁷

The concept of platform switching was introduced by Lazzara and Porter and refers to the use of a smaller-diameter abutment on a larger-diameter implant collar.¹⁰ Through the placement of smaller

¹Clinical Associate Professor, Department of Periodontology, Julius Maximilians-University, Würzburg, Germany.

²Private practice, Hürzeler/Zuhr, Munich, Germany.

³Clinical Associate Professor, Department of Operative Dentistry, Periodontology and Preventive Dentistry, University Hospital (RWTH), Aachen, Germany.

⁴Visiting Associate Professor, Department of Operative Dentistry and Periodontology, Albert Ludwigs University, Freiburg, Germany.

Correspondence to: Dr Stefan Fickl, Department of Periodontology, Julius-Maximilians-University, Würzburg, Pleicherwall 2, 97070 Würzburg, Germany. Email: fickl_s@klinik.uni-wuerzburg.de

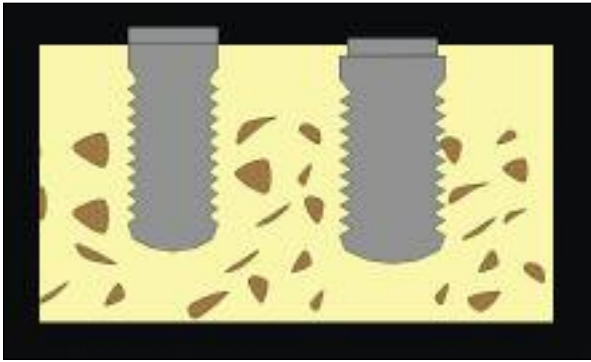


Fig 1 Schematic drawing of the location of the implant shoulder. The control implants (*left*) were placed epicrestally, while the platform-switched implants were positioned subcrestally.

prosthetic components on the implant platform, the implant-abutment junction is moved inward from the implant shoulder and further away from the bone, shifting the inflammatory cell infiltrate to the central axis of the implant and away from the adjacent crestal bone.¹⁰

However, there is limited scientific evidence supporting the concept of platform switching. Cappiello et al showed in a clinical study that platform switching decreased bone resorption to 0.95 mm compared to 1.67 mm in the control group.¹³ Previously published preliminary data from Hürzeler et al demonstrated furthermore that platform-switched implants exhibit statistically significantly less bone resorption than conventional implants.¹⁴

The purpose of this prospective clinical study was to evaluate whether the crestal bone height around dental implants could be influenced by a platform-switching protocol.

MATERIALS AND METHODS

All implants devoid of any need for additional bone augmentation placed between January 1 and December 31, 2006, in the Institute for Periodontology and Implantology, Munich, Germany, were included in this study. Situations involving immediate and delayed implant placement were excluded from this study. The same surgeon inserted all study implants.

1. Wide-diameter implants (Osseotite Certain, 5 mm, Biomet 3i) displaying a full Osseotite (dual acid-etched) surface and an internal connection were placed according to the manufacturer's recommendations, and a cover screw with a regular diameter (4.1 mm) was connected. All platform-

switched implants were placed in a subcrestal position and were submerged.

2. Control implants were Osseotite Certain standard-diameter implants with an internal connection (4 mm, Biomet 3i). All control implants were placed at the crest and submerged with a regular-diameter cover screw.

The location of the implant shoulder for both types of implants was verified clinically and with a postoperative panoramic radiograph (Fig 1). Second-stage surgery and connection of an implant-supported provisional prosthesis were performed following a 3- or 6-month healing period depending on the location of the implant (mandible/maxilla).

Three months after second-stage surgery, the definitive prosthetic reconstruction was placed. Standardized digital radiographs were obtained for evaluation of marginal bone levels at the time of placement of the definitive restoration and at 1 year of follow-up.

An image analysis program (Image Tool, University of Texas) was used to perform calibration and measurements. On the distal and mesial portions of the implant, the apical and coronal crestal bone intersects were marked. If possible, two or more marginal peri-implant bone levels were assessed. Calibrated measurements were conducted beginning from the marked bone intersects to the implant-abutment junction. For both the mesial and distal sides of each study implant site, the mean of the coronal and apical measurements was calculated. If only one measurement was available, that measurement was used as the value for the entire side (Fig 2).

The average value of the mean medial and mean distal values was calculated for each study implant site, and the resulting values were analyzed with an unpaired two-tailed *t* test. *P* values < .05 were regarded as statistically significant. All analyses were conducted using commercially available software (Graph Pad Prism, GraphPad Software).

RESULTS

In all, 36 patients (18 men, 18 women; age range 17 to 69 years, median 55.3 years) were included in this clinical investigation and gave their informed consent. Seventy-five implants were inserted with a platform-switched configuration, serving as the test group. Fourteen regular-diameter implants were placed and served as the control group. All inserted implants osseointegrated successfully, and all patients completed the 12-month follow up examination (Figs 3 and 4).

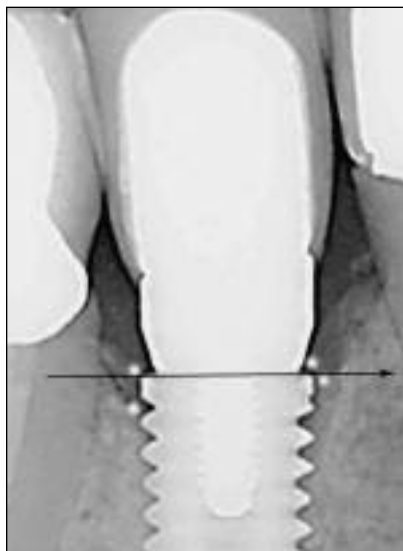


Fig 2 Illustration of the linear measurements. The apical and coronal bone intersects were marked on the distal and mesial aspects (white dots). A horizontal line was drawn at the level of the IAJ, and the distance to the bone intersects was measured.

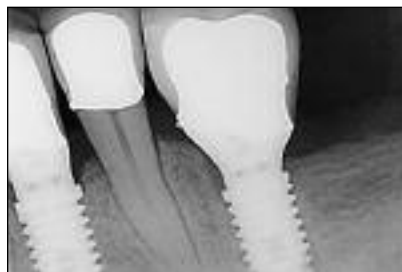

Fig 3a Standardized radiograph at the time of insertion of the definitive prosthesis displaying two platform-switched implants (mandibular left first premolar and first molar).

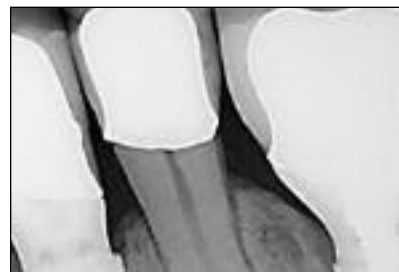

Fig 3b Standardized radiograph at 12 months of follow-up.

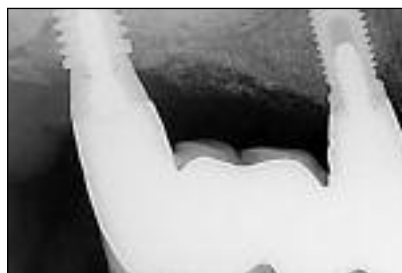

Fig 4a Standardized radiograph at the time of insertion of the definitive prosthesis demonstrating test and control implants in one patient.

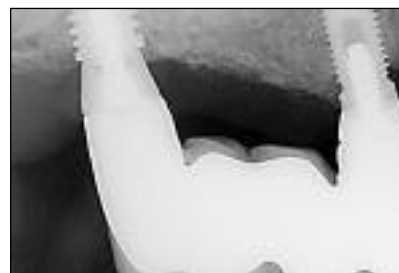

Fig 4b Standardized radiograph after 12 months in function. Note the difference in crestal bone loss around both types of implants.

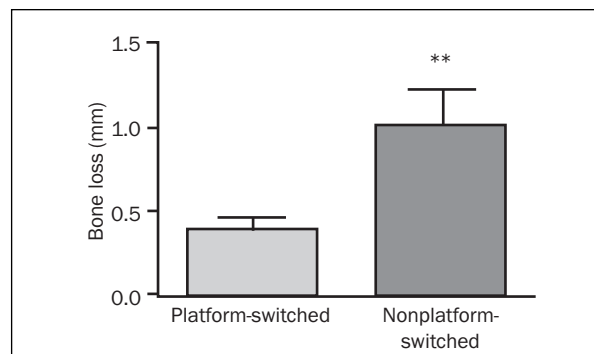
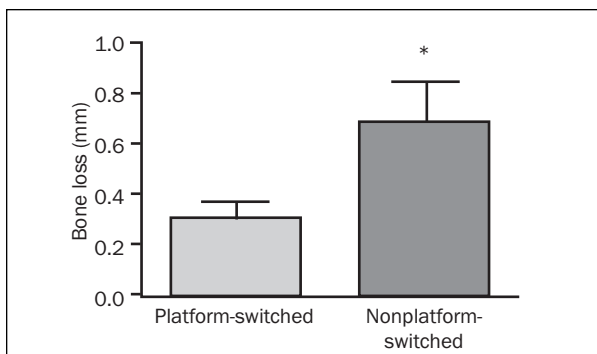


Fig 5 Significantly less bone loss was seen around platform-switched implants (left) at the time of insertion of the definitive prosthesis and (right) after 1 year of function. Data are presented as means \pm standard errors of the mean; statistical analyses were performed using two-tailed *t* tests for unpaired comparisons. **P* < .05, ***P* < .01.

The mean values of crestal bone loss at time of the insertion of the definitive prosthesis were 0.30 ± 0.07 mm for the platform-switched implants and 0.68 ± 0.17 mm for the nonplatform-switched implants. The two-tailed *t* test indicated that these differences were statistically significant (*P* < .05) (Fig 5, Table 1).

One year after the insertion of the definitive prosthesis, the mean crestal bone loss was 0.39 ± 0.07 mm for the platform-switched implants and 1.00 ± 0.22 mm for the nonplatform-switched implants. The two-tailed *t* test indicated that these differences were statistically significant (*P* < .01) (Fig 5, Table 1).

Table 1 Crestal Bone Levels Around the Platform-Switched and the Non-Platform-Switched (Control) Implants

Implant group	Prosthesis insertion*	12 mo	Difference
Platform-switched	0.30 (0.07)	0.39 (0.07)	0.10 (0.05)
Control	0.68 (0.17)	1.00 (0.22)	0.23 (0.18)

*Insertion of definitive prosthesis.

The mean amount of crestal bone loss between the insertion of the definitive prosthesis and the 1-year follow-up was 0.1 ± 0.05 mm for the platform-switched implants and 0.23 ± 0.18 mm for the nonplatform-switched implants. These differences were not statistically significant ($P > .05$) (Table 1).

DISCUSSION

Within the limits of the present study, the results confirm that implants with a platform-switched abutment can display decreased bone remodeling around dental implants 1 year after insertion of the definitive prosthesis. However, the results of this clinical trial should be analyzed with caution, as this study lacked inpatient control, and implants of varying diameters were compared with each other. Furthermore, the test and control implants were positioned differently with respect to the bone crest. This was done because implants with a platform-switched configuration are recommended to be placed subcrestally.^{10,13} It cannot be ruled out that this might have had an impact on bone remodeling.

The control group exhibited crestal bone loss of 1 mm 1 year after the definitive prosthetic reconstruction was placed. According to other studies, bone resorption has long been accepted as a physiologic response after two-piece implants are exposed to the oral cavity. Adell et al reported an average bone loss of 0.9 mm around submerged two-piece implants during the first year following restoration and less than 0.2 annually for the next 2 years.¹⁵ Several clinical studies have reported peri-implant bone resorption ranging from 0.4 to 1.5 mm by the end of the first year of loading.^{4,16-20}

In the present study, the implants reconstructed with platform-switched abutments revealed mean crestal bone loss of 0.39 mm 1 year after definitive prosthetic reconstruction. These results are in agreement with those of a clinical study by Cappiello et al¹³ reporting vertical bone loss between 0.6 and 1.2 mm with platform-switched implants 1 year after prosthetic reconstruction. They concluded that bone loss around platform-switched implants was significantly smaller than compared to the control group.¹³ In a human histologic case report, Degidi and Piattelli observed no bone remodeling around platform-switched implants 1 month after loading.²¹

Two principal reasons can be suggested for the reduced bone loss around platform-switched implants observed in the present study. First, from a mechanical viewpoint, it might be advantageous to shift the stress concentration area away from the cervical bone-implant surface to ensure less micromove-

ment in the adjacent bone structure. Maeda et al revealed in a finite element analysis that the platform-switching configuration leads to a decrease of the shearing stress at the bone-implant surface but increases the stress in the abutment or the abutment screw.²² Shearing stress and micromovements are thought to evoke bone resorption and bone disintegration in the affected sites.^{23,24} Duyck et al demonstrated that the magnitude and direction of implant loading (dynamic versus static versus no loading) had a statistically significant effect on crestal bone remodeling.²⁵ It may therefore be speculated that reduced stress in the coronal portion of platform-switched implants helps prevent crestal bone remodeling.

Second, from a biologic standpoint, it may be efficacious to shift the inevitable microgap of the IAJ away from the outer edge of the implant and neighboring bone. The IAJ is always encircled by an inflammatory cell infiltrate (ICT) (0.75 mm above and below the IAJ).¹² To protect the underlying bone from this inflammatory infiltrate and microbiologic invasion, 1 mm of healthy connective tissue is needed to establish a biologic seal comparable to that around natural teeth.^{12,26} Thus, a close proximity of the IAJ to the bone, which is always established when implants are placed epicrestally, is eliminated by bone resorption and establishment of the mentioned biologic seal. An internal repositioning of the IAJ by means of platform switching may decrease the effect of the abutment ICT on surrounding tissues. The reduced exposure and confinement of the platform-switched abutment ICT may result in a reduced inflammatory effect.

Recent literature has shown that various factors seem to be involved in crestal bone loss.^{10,27} Biomechanical factors such as surface topography of the collar,²⁸ platform width,²⁹ and the presence of coronal microthreads,³⁰ along with such procedure-associated factors as multiple abutment disconnection,³¹ have been demonstrated to influence crestal bone remodeling. This may be seen as a limitation of this study, as different implants were used in the test and control groups. In addition, the absence of inpatient control may be seen critically, as different healing patterns of patients and endogenous and local patient-related factors could have influenced the reported data.³²

CONCLUSION

Platform switching seems to limit crestal bone remodeling to a certain extent. This may be especially beneficial in esthetically demanding locations that require strong soft tissue support. Further studies need to elucidate the responsible mechanisms and confirm the long-term stability of the platform-switching technique.

ACKNOWLEDGMENTS

The authors declare that they have no conflicts of interest. The present study was partly funded by an unconditional grant from Biomet 3i. Dr Stefan Fickl is a recipient of the NYU International Fellowship Award granted by Biomet 3i. The authors acknowledge the valuable support of Dr Moritz Kebschull (Division of Periodontics, College of Dental Medicine, Columbia University, New York, New York) and James N. Kenealy, PharmD (Biomet 3i).

REFERENCES

- Jemt T, Chai J, Harnett J, et al. A 5-year prospective multicenter follow-up report on overdentures supported by osseointegrated implants. *Int J Oral Maxillofac Implants* 1996;11:291–298.
- Buser D, Mericske-Stern R, Bernard JP, et al. Long-term evaluation of non-submerged ITI implants. Part 1: 8-year life table analysis of a prospective multi-center study with 2359 implants. *Clin Oral Implants Res* 1997;8:161–172.
- Lambrech JT, Filippi A, Kunzel AR, Schiel HJ. Long-term evaluation of submerged and nonsubmerged ITI solid-screw titanium implants: A 10-year life table analysis of 468 implants. *Int J Oral Maxillofac Implants* 2003;18:826–834.
- Smith DE, Zarb GA. Criteria for success of osseointegrated endosseous implants. *J Prosthet Dent* 1989;62:567–572.
- Albrektsson T, Zarb G, Worthington P, Eriksson A. The long-term efficacy of currently used dental implants: A review and proposed criteria for success. *Int J Oral Maxillofac Implants* 1986;1:11–25.
- Berglundh T, Lindhe J, Ericsson I, Marinello CP, Liljenberg B, Thomsen P. The soft tissue barrier at implants and teeth. *Clin Oral Implants Res* 1991;2:81–90.
- Berglundh T, Lindhe J. Dimension of the periimplant mucosa. Biological width revisited. *J Clin Periodontol* 1996;23:971–973.
- Hermann J, Buser D, Schenk RK, Schoolfield J, Cochran DL. Biologic width around one- and two-piece titanium implants. A histometric evaluation of unloaded nonsubmerged and submerged implants in the canine mandible. *Clin Oral Implants Res* 2001;12:559–571.
- Hermann J, Cochran DL, Nummikoski P, Buser D. Crestal bone changes around titanium implants. A radiographic evaluation of unloaded nonsubmerged and submerged implants in the canine mandible. *J Periodontol* 1997;68:1117–1130.
- Lazzara RJ, Porter SS. Platform switching: A new concept in implant dentistry for controlling postrestorative crestal bone levels. *Int J Periodontics Restorative Dent* 2006;26:9–17.
- Oh T, Yoon J, Misch C, Wang H. The causes of early implant bone loss: Myth or science? *J Periodontol* 2002;73:322–333.
- Ericsson I, Persson LG, Berglundh T, Marinello CP, Lindhe J, Klinge B. Different types of inflammatory reactions in peri-implant soft tissues. *J Clin Periodontol* 1995;22:255–261.
- Cappiello M, Luongo R, Di Iorio D, Bugea C, Cocchetto R, Celletti R. Evaluation of peri-implant bone loss around platform switched implants. *Int J Periodontics Restorative Dent* 2008;28:347–355.
- Hürzeler MB, Fickl S, Zuh O, Wachtel H. Peri-Implant bone level around implants with platform-switched abutments: Preliminary data from a prospective study. *J Oral Maxillofac Surg* 2007;65:33–39.
- Adell R, Lekholm U, Rockler B, et al. Marginal tissue reactions at osseointegrated titanium fixtures (I). A 3-year longitudinal prospective study. *Int J Oral Maxillofac Surg* 1986;15:39–52.
- Morris HF, Ochi S. The influence of implant design, application, and site on clinical performance and crestal bone: A multicenter, multidisciplinary clinical study. Dental Implant Clinical Research Group (Planning Committee). *Implant Dent* 1992;1:49–55.
- Bengazi F, Wennstrom JL, Lekholm U. Recession of the soft tissue margin at oral implants. A 2-year longitudinal prospective study. *Clin Oral Implants Res* 1996;7:303–310.
- Ellegaard B, Kolsen-Petersen J, Baelum V. Implant therapy involving maxillary sinus lift in periodontally compromised patients. *Clin Oral Implants Res* 1997;8:305–315.
- Ross J, Sennerby L, Lekholm U, Jemt T, Grondahl K, Albrektsson T. A qualitative and quantitative method for evaluation of implant success: A five-year retrospective analysis of the Brånemark implant. *Int J Oral Maxillofac Implants* 1997;12:504–514.
- Behneke A, Behneke N, D'Hoedt B, Wagner W. Hard and soft tissue reactions to ITI screw implants: 3-year longitudinal results of a prospective study. *Int J Oral Maxillofac Implants* 1997;12:749–757.
- Degidi M, Piattelli A. Immediate functional and non-functional loading of dental implants: A 2- to 60-month follow-up study of 646 titanium implants. *J Periodontol* 2003;74:225–241.
- Maeda Y, Miura J, Taki I, Sogo M. Biomechanical analysis on platform switching: Is there any biomechanical rationale? *Clin Oral Implants Res* 2007;18:582–584.
- Sugiura T, Horiuchi K, Sugimura M, Tsutsumi S. Evaluation of threshold stress for bone resorption around screws based on in vivo strain measurement of miniplate. *J Musculoskelet Neuronal Interact* 2000;1:165–170.
- Tuner C. On Wolff's law of trabecular architecture. *J Biomech* 1992;25:1–9.
- Duyck J, Ronold HJ, Van Oosterwyck H, Naert I, Vander Sloten J, Ellingsen JE. The influence of static and dynamic loading on marginal bone reactions around osseointegrated implants: An animal experimental study. *Clin Oral Implants Res* 2001;12:207–218.
- Waerhaug J. Subgingival plaque and loss of attachment in periodontosis as evaluated on extracted teeth. *J Periodontol* 1977;48:125–130.
- Hermann F, Lerner H, Palti A. Factors influencing the preservation of the periimplant marginal bone. *Implant Dent* 2007;16:165–175.
- Cosyn J, Sabzevar MM, De Wilde P, De Rouck T. Two-piece implants with turned versus microtextured collars. *J Periodontol* 2007;78:1657–1663.
- Baggi L, Cappelloni I, Di Girolamo M, Maceri F, Vairo G. The influence of implant diameter and length on stress distribution of osseointegrated implants related to crestal bone geometry: A three-dimensional finite element analysis. *J Prosthet Dent* 2008;100:422–431.
- Schrotenboer J, Tsao YP, Kinariwala V, Wang HL. Effect of microthreads and platform switching on crestal bone stress levels: A finite element analysis. *J Periodontol* 2008;79:2166–2172.
- Abrahamsson I, Berglundh T, Lindhe J. The mucosal barrier following abutment disconnection. An experimental study in dogs. *J Clin Periodontol* 1997;24:568–572.
- van Steenberghe D, Jacobs R, Desnyder M, Maffei G, Quirynen M. The relative impact of local and endogenous patient-related factors on implant failure up to the abutment stage. *Clin Oral Implants Res* 2002;13:617–622.